



PRESENTING CLINICAL SIGNS

History: Grade 4/6 murmur.

DATE

12/27/22

ECHOCARDIOGRAPHIC FINDINGS

2D, M-mode, and Doppler study. (NOTE: Some images for Luna are labeled Sarah Medina).

PERFORMED BY:

Rebekah Jakum

INTERPRETED BY

Keith Blass, DVM,
MS, DACVIM
(Cardiology)

There is mild left atrial dilation. The mitral valve leaflets are thickened and exhibit mild systolic prolapse. A moderate jet of eccentric mitral regurgitation is present. There is mild left ventricular dilation. Left ventricular systolic function is hyperdynamic. The aorta and aortic valve are normal. Right atrial and right ventricular dimensions are normal. The tricuspid valve leaflets are mildly thickened, and a mild jet of tricuspid regurgitation is present. TR velocity does not suggest the presence of pulmonary hypertension. The pulmonary artery and pulmonic valve are normal. No shunting lesions are visualized. No heartworms are visualized. No pericardial effusion or cardiac masses are seen.

PATIENT

Luna Lovegood

LA - 30.4 mm
LVIDd - 29.0 mm
LVIDs - 15.2 mm
FS - 47.6%
RA - 17.1 mm
LVOT - 1.59 m/s
RVOT - 1.19 m/s
TR - 2.08 m/s

SPECIES

Canine

ASSESSMENT/RECOMMENDATIONS

Degenerative mitral and tricuspid valve disease

BREED

Chinese Crested

This examination demonstrates regurgitation of blood across Luna's mitral and tricuspid valves resulting from degenerative valve disease. Luna's tricuspid valve disease is mild, and is well-compensated at this time. Her mitral valve disease is more advanced, as Luna has moderate mitral regurgitation present, with mild secondary dilation of both her left atrium and left ventricle. As only mild left heart chamber dilation is present, Luna's current risk for the development of clinical signs secondary to her mitral valve disease, such as coughing, exercise intolerance, syncope, and labored breathing, appears to be relatively low, though careful monitoring for these signs is recommended going forward.

SEX

FS

I recommend starting Luna on pimobendan (2.5 mg am, 1.25 mg pm), as this medication should help to slow the progression of her mitral valve disease.

AGE

7 y

A recheck echocardiogram is recommended in 6-9 months. Thoracic radiographs are recommended if Luna experiences respiratory clinical signs.

WEIGHT

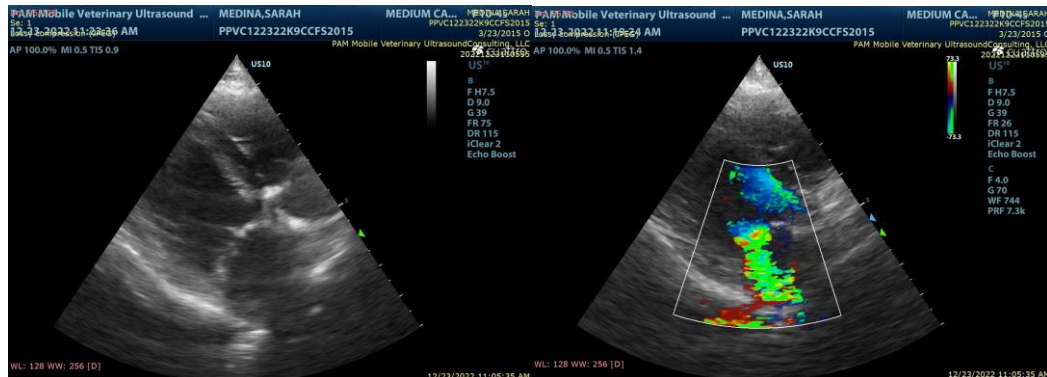
16.3 lb

HOSPITAL NAME

Pocono Peak VC

REFERRING VET

Dr. Thompson





DATE 12/27/22
The information and recommendations provided are based on the images presented by the referring veterinarian. No evaluation can be communicated regarding pathology that was not visible in the image/video clips provided.

PERFORMED BY: Rebekah Jakum
Thank you for this referral. If the clinical or image interpretation does not parallel your findings or if I can be of any further assistance please contact me.

INTERPRETED BY Keith Blass, DVM, MS, DACVIM (Cardiology)
KeithBlass@gmail.com
631-804-5754

Keith Blass, DVM,
MS, DACVIM
(Cardiology)

PATIENT

Luna Lovegood

SPECIES

Canine

BREED

Chinese Crested

SEX

FS

AGE

7 y

WEIGHT

16.3 lb

HOSPITAL NAME

Pocono Peak VC

REFERRING VET

Dr. Thompson